

Case Report

A Rare and Underestimated, However, A Treatable Disease: Tarlov Cyst and Adhesive Arachnoiditis

Dr. Lidia Sarnataro MD MS*

*Corresponding Author: Dr. Lidia Sarnataro, E-mail: lidiasarnataro@gmail.com

ARTICLE INFO

Article history

Received: July 28, 2022

Accepted: September 16, 2022

Published: October 31, 2022

Volume: 10 Issue: 4

Conflicts of interest: None.

Funding: None.

Key words:

Tarlov cyst,
Isador Max Tarlov,
CSF,
Arachnoiditis,
Syringomyelia,
ACM,
Ehlers-danlos syndromes,
Stem cells

ABSTRACT

Tarlov cyst (TCs) is also called perineural cyst, which is a rare disease of the posterior nerve root prevalently localized in the lumbo-sacral region, however, it is also possible in every part of the spinal cord. These cysts represent a dilation of the nerve-root sheath that often communicate with subarachnoid space through a valve-like mechanism containing cerebrospinal fluid (CSF) and neural tissue. Tarlov cyst is often asymptomatic and discovered incidentally in the MRI, however, sometimes it can be symptomatic and is characterized by many symptoms, such as low back pain, sacral radiculopathy, sciatica, coccydynia or cauda equina syndrome, constipation, dyspareunia, urinary incontinence, and retention as well as blurry vision and headache. Moreover, these cysts can be a cause of CSF leak and therefore culprit of idiopathic intracranial hypotension. The etiopathogenesis is still unclear, but it is documented that a trauma, an old hemorrhage, and congenital and iatrogenic causes may be responsible for it. Association between the Tarlov cysts and the arachnoiditis have been studied in the last years. Tarlov cyst appears to be a consequence of the arachnoiditis. In general, there are four stages of arachnoiditis. In the last stage, it is possible that some patients cannot walk anymore becoming wheelchair bound. Moreover, arachnoiditis is often associated to type I ACM, syringomyelia and Ehlers-Danlos syndromes. Although Tarlov cyst has been known since 1938, the year in which Dr. Isador Max Tarlov described it first as an incidental finding in cadavers, nowadays many doctors do not really know this disease and underestimate it by thinking that it cannot be responsible for the above listed symptoms. The main aim of this work is to educate the medical community to consider Tarlov cyst in the differential diagnosis of back pain patients, and in other diseases. While the surgery represents the most effective therapy for such patients, a treatment of the arachnoiditis with the stem cells therapy should be also considered.

INTRODUCTION

Tarlov cyst is nowadays becoming more commonly diagnosed because of the imaging technology, such as computerized tomography scan and MRI. As the cysts in the lumbo-sacral region of the spinal cord can dissimulate abdominal masses, it is important to know this illness to make a precise differential diagnosis. When in 1938 Dr. Isador Max Tarlov first described the presence of extradural cysts of the posterior nerve root in the sacral and coccygeal region of 30 cadavers, he discovered a new pathology that took his name. However, cases of four thoracic and one lumbar cyst were already described respectively in 1902 by Marburg and in 1932 by Hirnrichs. Then Tarlov could not clarify the cyst predilection for the sacral area, however, in 1952, he decided to make a clinical correlation of his findings in cadavers with the symptoms of a herniation of nucleus pulposus lumbo-sacral such as a radiculopathy in the lumbo-sacral region. Exactly, Tarlov cysts also known as perineural cysts or di-

verticula of the nerve root or meningeal cysts, or sacral cysts or arachnoid cysts are cystic formations in the subarachnoid space between the perineum and endoneural sheet especially in the sacral region at the level of the junction of the dorsal root with the spinal ganglion. New studies showed evidence of an anatomical communication with the subarachnoid space even without the input of an iatrogenic cause. The corresponding compression of the adjacent structures is then responsible for the symptoms (1. De Sá MC, et al, 2008).

Classification

According to Nabor's classification of spinal meningeal cysts, it is possible to describe 3 types of cysts: extradural cyst without nerve-root fibers, extradural cyst with nerve-root fibers, and intradural cyst. In the type I, there are also two subgroups: IA extradural meningeal/arachnoid cysts, and IIB sacral meningocele (Table 1). Tarlov cysts are nor-

Table 1. Classification of spinal meningeal cysts

Classification of spinal meningeal cysts			
According to Nabor	I Extradural cyst without nerve-root fibers	II Extradural cyst with nerve-root fibers (Tarlov cyst)	III Spinal intradural arachnoid cysts
	IA Extradural meningeal/ arachnoid cysts		
	IB Sacral meningocele		

mally type 2 spinal meningeal cysts, nevertheless a proper differentiation is only possible on histological inspection (1. De Sá MC, et al, 2008).

Epidemiology

Paulsen reported a prevalence of the disease of 4,6% in back pain patients (n= 500), but only 1% was symptomatic.

While, in the literature, according to Larsen, et al in 1980, the incidence of Tarlov cysts varies widely with a highest general incidence of 17,65%, Klepinowski, et al (7.) described in 2021 in a meta-analysis of 22 radiologic studies of level 3 evidence involving 13,266 subjects that the global pooled prevalence of Tarlov cysts was 4.18% with a mean pooled sagittal diameter of 11.86 mm, the sacral area and especially the S2 level (46.7%) was the most common area affected. Women are more prone than men with a percentage of 5.84% versus 3.03%. Geographically, the highest incidence was found in Europe (6.07%), followed by North America (3.82%), and Asia (3.33%). In pediatric population, Tarlov cysts are rare (0.53%). Generally, the incidence of symptomatic Tarlov cysts is 15.59%. Exactly, a gender-specific prevalence was observed in 8 studies. For example, in women, the prevalence was 7.01% in comparison to 4.05% in men. In kids, TCs are an exceptional finding. The hypothesis is that TCs in adult female patients can be associated to the level of female sex hormones. To confirm this hypothesis case-control studies using a group with hypogonadism and a group of healthy people.

In another study published in the Journal of Neuroradiology of February 2017, (9. Kuhn Félix P, et al) considered the prevalence of simple and complex sacral perineural (Tarlov cysts) in a French cohort of children and adults. An MRI scan was performed in children, adolescents, and adults. No cysts were found in children, but 132 adult patients (13.2%) with a female and age predominance (68%) had 263 sacral cysts. A maximum of 6 cysts was described in a single patient. Most of the cysts (87.5%) were simple with a homogenous central fluid collection and a parietal course of the nerve fibers, but 33 cysts (12.5%) had complex patterns and exactly 28 cysts had an endocystic crossing of nerve fibers and 5 an internal septations. Finally, 70 cysts (26.6%) caused an erosion in the adjacent bone and 13 cysts (4.9%) progressed to the pelvis. Generally, the prevalence of Tarlov cysts amounted to 13% in a female and age predominance and no cysts were found in children and adolescents.

Etiopathogenesis

As Tarlov was studying Marburg's theory about the four findings of cysts in the thoracic spinal cord being caused by

hemorrhage, he elaborated his own theory about an inflammatory event in the nerve membranes followed by the entrance of fluid coming from a transudate of the vessels in the perineural space filling up the cyst more and more. He knew that Elsberg, Dyke, and Brewer were suggesting a congenital origin of a diverticulum of the dura mater, or an arachnoid herniation caused by a congenital defect of the dura mater. In 1952, he also described two autopsy findings of a sub-aracnoidal hemorrhage causing the rupture of veins in the nerve root and in the ganglion or their infiltration and finally destroying the nerve and forming the cyst. Exactly, there were examined many causes such as degenerative, congenital, inflammatory, and traumatic or iatrogenic that is caused by medical procedures such as rachiocentesis, myelography, peridural anesthesia but the etiopathogenesis is still unclear. However, all these theories can be possible depend on the patient's anamnesis (1. De Sá MC, et al, 2008).

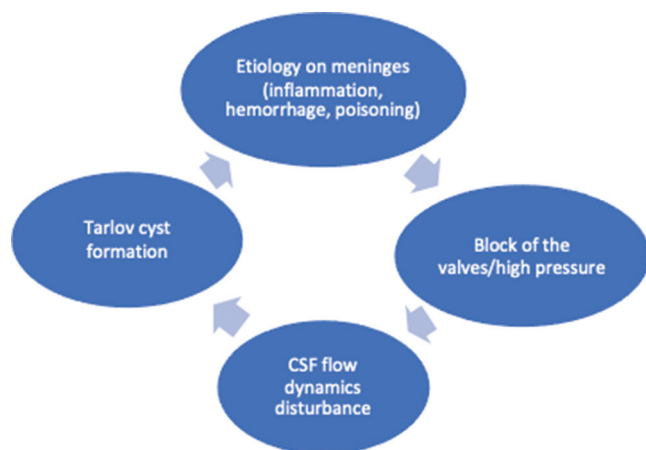
Nevertheless, since Tarlov cysts represent a dilation of the nerve-root sheath that often communicate with subarachnoid space through a valve-like mechanism containing cerebrospinal fluid (CSF) and neural tissue, the mechanism that seems responsible for the cyst formation is a disturbance of the CSF flow dynamics secondary to an etiology that leads to inflammation or hemorrhage or even chemical poisoning in the meninges, causing a block of the valves and a high pressure (Graphic 1). In fact, normally, in case of a high pressure, the CSF can drop out through a pressure valve system working at the lower end of the arachnoid space. Then, there is a mechanism of absorption through venous structures around the spinal nerve root ganglions outside the spinal canal (3. Warnke JP, 2021).

In Prof. Warnke's experience, as he said in his presentation on a crowdcast on 17th of March 2021, "Talov cysts are associated to a Leptomeningopathy or an Arachnoiditis."

Leptomeninges or Arachnoiditis and its Association with TC and other Neurological Diseases

While a Leptomeningopathy is an inflammatory process concerning the Pia mater and the Arachnoid, adhesive arachnoiditis also called spinal arachnoiditis is characterized by an inflammation of the arachnoid membrane. This inflammation can bring to changes in the flexibility of the nerve roots and reduce the pressure regulatory capacity. This leads to a distortion of rootlets as well as a chronic elevated CSF pressure with venous congestion, and generally to CSF flow disturbances with formation of cysts at places of low resistance (3. Warnke JP, 2021).

However, considering that the Leptomeninges have a slow metabolism, after the cause of the illness occurs, many years can pass by before the symptoms start. The etiology is



Graphic 1. Etiopathogenesis of the TCs.

still unclear, but many medical procedures - such as lumbar punctions, peridural anesthesia, and epidural cortisone infiltrations - might be responsible for it. However, just few people develop this rare disease. Then, it is possible that a special factor together with one of the probably listed causes can lead to this condition. There are signs that an autoimmune disease could make possible this typical chronic inflammation of the arachnoids. In general, evidence is still not enough but a research program is being conducted by the Vidgis Thompson Foundation (4. Vidgis Thompson Foundation, 2022).

In general, it is possible to divide Arachnoiditis in four degrees according to Hoffmann (Table 2):

- Arachnoiditis Grade I: the Arachnoid has light changes.
- Arachnoiditis Grade II: Pia mater and Arachnoid are milky and thick instead to be shining.
- Arachnoiditis Grade III: calcifications around the nerve roots occur, the nerve roots are stuck to each other.
- Arachnoiditis Grade IV: the CSF has lost its space and it is full of scar tissue. This grade is very rare to see (3. Warnke JP, 2021).

However, often the disease remains in the same grade without reaching the highest level (4. Vidgis Thompson Foundation, 2022).

In medical literature, many types of arachnoiditis were described: adhesive, oblitrans (35. So Yoon Ahn, et al, 2014), ossificans (10. Writh M H, et al, 2003), tuberculous (11. Demetriades A K, 2020; 12. Heidary M, et al, 2021; 13. Holly LT, et al, 2019; 14. Klekamp J, et al, 2002), and aseptic after medical procedures (4. Vidgis Thompson Foundation, 2022). Moreover, in 2008, in an article on Medical News Today, some other types, such as cerebral, hereditary, neoplastic and optochiasmatic – i.e., behind the optic nerve - arachnoiditis were also described.

Since arachnoiditis can mimic many other diseases including spinal cord tumors, arachnoiditis ossificans, syringomyelia, sciatica pain and a cauda equina syndrome (10. Writh MH, et al, 2003), it is often misdiagnosed and not recognized as a disease by many doctors. Nowadays, there is not a treatment for this disease and research using stem cells therapy should be taken into consideration.

In medical literature, associations between arachnoiditis and other diseases were found.

Table 2. Arachnoiditis classification according to hoffmann

Grade I	Grade II	Grad III	Grade IV
Light changes in the arachnoid	Pia mater and arachnoid thick	Calcifications around the nerve roots and adhesive changes	Completely full of scar tissue, no space for CSF

For example, reports describe a Chiari I malformation after a distal tuberculous arachnoiditis in the lumbar spine. Another association is also between arachnoiditis and syringomyelia. However, the pathophysiology beyond these connections is still unclear (11. Andreas K Demetriades, 2020; 12. Heidary M, et al, 2021; 13. Holly LT, et al, 2019; 14. Klekamp J, et al, 2002).

Unlikely Chiari from types 2 to 4, Chiari I malformation should be considered as a syndrome and, therefore, called Chiari syndrome (15. Radek Fric, et al, 2019).

A case of Arnold Chiari syndrome was documented in a 53-year-old woman with papilledema, that was already treated oncologically and surgically because of a right breast tumor 4 years ago. In a brain MRI, a suspicion of metastasis could be excluded, and a Chiari malformation was diagnosed. Then it is to suppose that the papilledema was an expression of the intracranial hypertension mainly caused by the Chiari malformation (16. Zatorska B, et al, 2004).

Another case of idiopathic intracranial hypertension and Chiari deformity was described in an obese pregnant woman. In this case, the cerebral CT scan was normal. After acetazolamide use, she had an alteration of her neurologic state and ocular motility. MRI was performed and showed a type I ACM. First, a decompression of the cerebrospinal fluid (CSF) by superior way and then a neurosurgical surgery for the Chiari malformation were conducted leading to a total patient's recuperation. A lumbar puncture could be fatal. Maybe, in this case, the idiopathic intracranial hypertension was responsible for a decompensation of the ACM (17. Demols P, et al, 1998).

Arachnoid granulations known as (AGs) were found in patients with idiopathic intracranial hypertension known as IIH. In a retrospective chart review study, 79 patients with a diagnosis of IIH were compared with 63 patients with multiple sclerosis. The inclusion criteria were an MRI of the brain, and female patients older than 18 years old. Finally, the percentage of patients with AGs was higher in the group with IIH. The MRI findings showed an empty sella and a prominent cerebrospinal fluid space in the optic sheaths. In these patients, the relationship between AGs and IIH can be explained as a compensatory mechanism in the arachnoid because of the IIH (18. Watane G V, et al, 2018). A case of adhesive arachnoiditis and dorsal syringomyelia secondary to subarachnoid hemorrhage was also described (19. Galiano R, et al, 2013).

In another article, a 66-year-old patient with primary Sjögren syndrome had a syringomyelia after two subarachnoid hemorrhages (SAHs) due to rupture of basilar artery aneurisms. Exactly, three years after the last SAH, she started

to have gait disturbance and pain in the abdomen and feet. An MRI showed a syringomyelia in the thoracic cord from T2 to T11 and multiple arachnoid cysts in the ventral side of the spinal cord. A CT myelography demonstrated a complete block of the CSF flow at T7. A surgery with microlysis of the adhesions and CSF restoration was performed. Afterward, the patient could walk again but the abdominal paresthesia was not improved. An MRI showed a reduced size of the syrinxes. This teaches that it is important to recognize that a late complication of SAH could be syringomyelia and arachnoid cysts and that a surgical treatment is the best choice to improve this condition (20. Ishizaka S, et al, 2012).

To better understand the possible connections between the three diseases, namely arachnoiditis, type 1 ACM and syringomyelia, this last medical condition will be described in detail below.

Syringomyelia means “cavity within the spinal cord” and is a progressive chronic condition (21. Vandertop WP, 2014). The syrinx can be considered as a fluid-filled, gliosis-lined cavity in the spinal cord parenchyma, or a focal dilatation of the central canal called hydromyelia (22. Milhorat TH, 2000). There is a congenital form, or more exactly two types (23. Ikenouchi J, et al, 2002), caused by abnormality of primary neurulation, and an acquired one. In the first form, we can distinguish an embryogenic type and a fetal one. While the embryogenic type has an abnormal dilatation of the spinal cord canal and a lack or absence of mesenchymal tissue between the spinal cord and the ectoderm; the fetal one does not show an affection of the mesenchymal tissue, therefore, the vertebral column is intact. The acquired form is characterized by disturbance of normal cerebrospinal fluid flow movement. The most common etiologies of the congenital form are neural tube defects and *Chiari-I malformation*. In Chiari-I malformation, there is a downward herniation of the cerebellar tonsils, that blocks the CSF flow during the cardiac cycle and Valsalva maneuvers. In this case, the CSF can accumulate either in the central canal or spinal cord parenchyma. In the acquired form, causes can be secondary to hydrocephalus; infection, such as a meningitis (21. Vandertop WP, 2014); inflammation including transverse myelitis, sarcoidosis and multiple sclerosis (24. Ravaglia S.; et al, 2007; 25. Charles JA, et al, 2004; 26. Marangoni S, et al, 2006); trauma, such as surgery and arachnoid scarring in *adhesive arachnoiditis*; extramedullary lesions, such as tumors and arachnoid cysts; intramedullary tumors and especially ependymomas and hemangioblastomas; and also spinal canal stenosis especially in the cervical area. Patients with syringomyelia can be asymptomatic or have pain, weakness, and stiffness in the back, shoulders, and extremities. They can experience a loss of their ability to feel extreme hot or cold in their hands, and then a loss of pain and temperature sensation in the back and arms. In the end-stage, an autonomic bladder and a bowel dysfunction can also appear. In the congenital form with a neural tube defect, the patients have neurological deficits in the lower extremities, bladder and bowel dysfunction and pain. Scoliosis is often described, especially in patients with a terminal syrinx (27. Iskandar BJ, et al, 1994), but the ones having an extension of the syringomyelia in the cervical spi-

nal cord also have hand weakness and sensory symptoms like a Chiari-II malformation. The diagnosis is done through an MRI. Especially, it is possible to use an electrocardiographically gated flow-sensitive techniques, such as four-dimensional (4D) phase contrast (PC) MRI, for a good study of CSF flow circulation in order to distinguish pathological flow patterns at the craniocervical junction and also cervical and thoracic spine, and even to detect cystic spaces not communicating with normal CSF spaces (28. Chavhan GB, et al, 2008; 29. Roser F, et al, 2008; 30. Bunck AC, et al, 2011). In asymptomatic syringomyelia, the therapy is “wait and watch,” instead the symptomatic syringomyelia is treated in a nonsurgical way with medication. In neural tube defects, a shunt revision is often associated with an improvement of the symptoms, however, in case of unsuccess, the untethering of the cord is considered beneficial (31. Vandertop WP, 2003).

In other cases, for example like Chiari-I malformation, it is important a surgical treatment with a craniocervical decompression and an augmentation duraplasty. In arachnoid scarring, such as the case of adhesive arachnoiditis, localized bands of fibrosis can be sectioned performing an adhesiolysis, however, in a widespread arachnoiditis with infiltration of dura, arachnoid and pia mater, sometimes this is impossible, and the only solution is a direct drainage of the syrinx. Postoperative complications can be infection, hematomas, and scar formation around the spinal cord or implanted shunts, wound leakage of CSF, and shunt obstruction. The prognosis is not good, since it is a progressive chronic disease with remissions and exacerbations, that often require surgical intervention to avoid a loss of functions (21. Vandertop WP, 2014).

And finally, there is also an association with Ehlers-Danlos syndromes (EDS). To describe briefly what EDS are, we can say that these conditions are a heterogeneous group of heritable connective tissue disorders. Patients suffering with these syndromes have normally joint hypermobility, skin extensibility, and tissue fragility. This leads to neurological manifestations, such as weakness of the ligaments of the craniocervical junction and spine, early disc degeneration and weakness of the epineurium and perineurium around the peripheral nerves. A prevalence of IIP and TCs were reported but unfortunately there is not real epidemiological evidence. Even Chiari Malformation Type I can be a comorbid condition in such patients (41. Henderson FC Sr, et al, 2017).

Symptoms

Although most of the patients with Tarlov cyst are asymptomatic, some are symptomatic with musculoskeletal pain in the lumbo-sacral region, sacral radiculopathy, sciatica, coccydynia or cauda equina syndrome, constipation, dyspareunia, urinary incontinence, or tenesmus as well as blurry vision and headache. Also, buttocks pain, vaginal or penile paresthesia or sensory changes over the buttocks were described.

According to Paulsen, 1% of 500 patients with pain in the lumbo-sacral region and radiculopathy was showing a Tarlov cyst on the MRI. The symptoms are caused by the cyst compression on the nerves and the bones in the lum-

bo-sacral as well coccygeal and pelvic region. Some people can have sacral pain because of the cyst growth within the bone, or enormous Tarlov cysts can break causing an immediate intracranial hypotension with stupor (1. De Sá MC, et al, 2008). Normally, the symptomatology is intermittent and exacerbated by standing, walking, and coughing. The pain is alleviated by bed rest (34. Dehaine V, et al, 1990).

In an article of the *Journal of Spinal Disorders & Techniques* published on February 2005, Langdown AJ, et al (8.) studied the clinical relevance of Tarlov cysts. Over a 5-year period, 3535 patients underwent an MRI scan for lumbosacral symptoms. Fifty-four patients had Tarlov cysts, and their symptomatology was correlated with the MRI findings. The results showed that the majority of Tarlov cysts ($n = 38$) were not responsible for patient's symptoms; in some patients ($n = 9$), cysts were at the same level as another pathology and did not require any specific therapy; and finally, a smaller subgroup of cysts ($n = 7$) was responsible for patient's symptoms and required specific treatment.

In 2007 in the *Indian Journal of Orthopedics*, Bhagwat P, et al (2.) reported a case of a 29-year-old female with right quadriceps pain for nine months. At the beginning the pain could be relieved by NSAID but in the last three months it had increased progressing to the lower back and bilateral upper quadriceps down to the ankle. A pain worsening was observed after activity, prolonged standing during the evening. The patient woke up in the middle of the night with pain, afterwards she had pain in rest of her body as well. The clinical examination did not reveal any specific findings. X-ray of the lumbosacral spine were normal, but an MRI revealed a 2 cm fluid-filled cystic in the S2 on the right side. A sacral laminectomy with excision of the cyst and plication of the cyst wall was performed. In the histopathological examination, the diagnosis of Tarlov Cyst was confirmed. After the surgery, the patient had an immediate relief from the pain and no problems on the postoperative period. On her nine months follow-up, the patient was asymptomatic and went back to work, an MRI showed no recurrence of the cyst.

In 2020, in the Spanish journal "Rehabilitación", Fernández-Cuadros, et al (5.) presented a case of a 70-year-old female patient with fecal incontinence because of a Tarlov cyst. In the *AJOG* (American Journal of Obstetrics & Gynecology) on January 2020, Lim V M, et al (6.) also published a retrospective study on 242 patients with pudendal neuralgia, that have undergone a pelvic MRI from January 2010 to November 2012. Totally, there were found 50 Tarlov cysts at the S2-S3 level in the patient cohort. The study showed that Tarlov cysts were not the cause of the pudendal neuralgia, however, both could have a similar pathogenesis as a part of a focal or generalized condition.

Moreover, in 1990 in "La Revue de médecine interne", 34. Dehaine V, et al 1990, described a case of coccygodynia in TC. A 63-year-old male patient complained about coccygodynia and then an incomplete cauda equina syndrome. A large perineural cyst on the sacral nerve roots was suspected in the CT and MRI and then confirmed in a sacculoradiculography. Intradural injections of corticosteroids gave the patient a long-lasting pain relief. In general, TC have

characteristic symptoms, that are paroxysmal, exacerbated by standing and relieved in dorsal position. In this case, the pain can be revived by percussing the sacrum.

Diagnosis

The diagnosis of a Tarlov cyst is difficult because of the variety of unspecific symptoms and the respective differential diagnoses, such as degenerative spine diseases, spine canal stenosis, discal herniations, tumors and inflammatory spine diseases. These conditions cause symptoms due to pression and irritation of the nerves, while arachnoiditis and its consequence, the Tarlov cyst, are the result of a real nerve inflammation (4. Vidgis Thompson Foundation, 2022).

Moreover, many doctors do not have the knowledge to identify it and even the radiological centers do pay more attention to common diseases like protrusions and discal herniations as described above. Normally, in an X-ray, it is possible to observe signs of erosions in the sacral region and paravertebral hypodense images and even a sacral fracture. A computerized tomography can show isodense cystic masses with CSF at the foramina. Many years ago, in a case the diagnosis was unclear, a CT myelography was performed to demonstrate the filling of the meningocele sac one hour after the injection of contrast medium, and generally a communication between the cystic subperineural and the subarachnoid space. However, because of the pulsatile pression of the CSF, the contrast can reach the cyst after many hours or weeks, therefore, it is important to perform a second test to avoid a false negative. A bone erosion with thick edges and a cystic formation can be seen in a computerized tomography. A MIELOCT can ameliorate the possibility to diagnose the TC. However, MRI is the gold standard to see the cyst, its expansion in the sacral canal, the enlargement of the neural foramen, and the compression of the adjacent nerves (Figures 1 and 2). An electromyography of the sacrococcygeal roots can help to identify the grade of the sufferance of the roots and myotomes (1. De Sá MC, 2008).

The diagnosis of aseptic arachnoiditis is even more complicated. However, the two conditions have a correlation shown in the MRI. While, in earlier stages, it is possible to see indirect signs of arachnoiditis; in later ones, this disease can rarely be diagnosed through a contrast enhancement in the Leptomeninges in the acute phases. If an MRI is unclear, the examination and the anamnesis can help to diagnose it (4. Vidgis Thompson Foundation, 2022).

Treatment

After his discover, Tarlov even started to advise for a surgical treatment with sacral laminectomy and total excision of the cyst and the nerve root.

Normally, a Tarlov cyst smaller than 1,5 cm without bone alterations does not require a surgical therapy but a bigger cyst should be treated surgically. However, there is not a fix treatment regimen. According to Roche, there are two steps in the treatment: one clinic consisting in pain killers and myorelaxants, and the second surgical performing a laminectomy. Dehaine uses in the clinical phase anti-in-

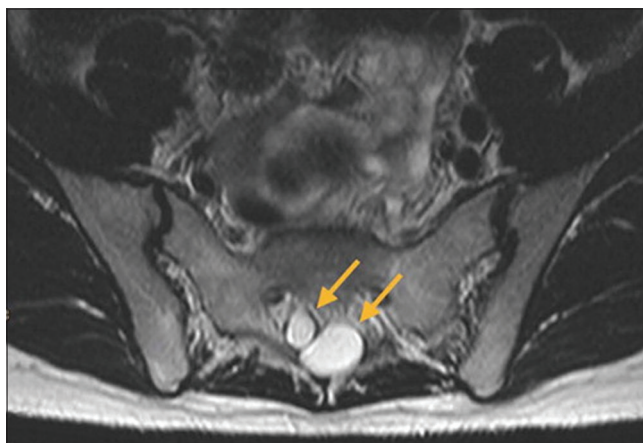


Figure 1. Axial T2-weighted magnetic resonance imaging of the lumbosacral spine revealing perineural (Tarlov) cysts (arrows) at the level of S2.

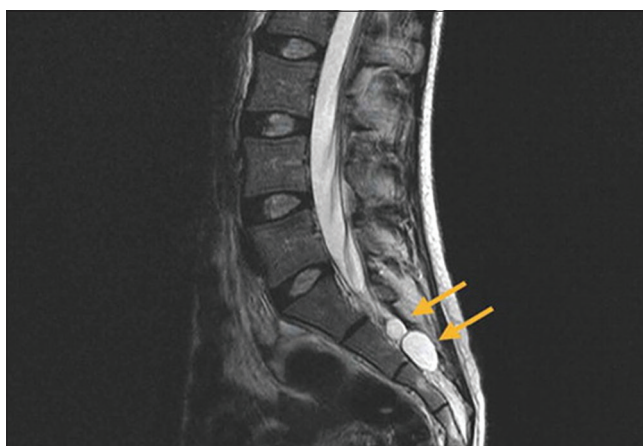

Figure 2. Sagittal T2-weighted magnetic resonance imaging of the lumbosacral spine revealing perineural (Tarlov) cysts (arrows) at the levels of S2 and S3.

inflammatory drugs and local injections of corticosteroids. De Sá recommends the use of pain killers, anti-inflammatory drugs, antidepressants, and physical therapy. Magalhães described a remission of neuropathic pain in a patient with Tarlov cysts in the roots of S1, S2 and S3 after a treatment with Gabapentin in progressive doses to 900 mg once/daily. Other non-surgical therapies include as reported by Paulsen a percutaneous drainage of the cyst under computerized tomography, however, a liquor fistula can happen. The surgical treatment is a sacral laminectomy for a microsurgical fenestration of the cyst. This is then followed by a duroplasty or plication of the cyst wall. According to Caspar, this is a safe and effective treatment (1. De Sá MC, et al, 2008).

In general, together with the medical treatment and/or before or after the surgical procedure physical therapy can be helpful to strengthen the muscles; moreover massages may reduce muscle tension, and cold packs can relieve temporarily the inflammation (40. Villines Z, et al, 2018).

In 2017, in the *World Neurosurgeon*, 32. Juan D. Del Castillo-Caláneo, et al described a case of a 29-year-old woman with pain and weakness in the right lower extremity. In the MRI, a TC in the right L5-S1 was shown. Later, it was

performed a small laminotomy with cyst drainage followed by neck ligation using a Scanlan modified technique through tubular retractors. In the first postoperative days, the patient had a full recovery of the motor function and no relapse at 6-month follow-up.

In another article published by Juan Mezzadri, et al (33.) in 2014 on the *Journal of neurological surgery, part A, Central European neurosurgery*, it was described the endoscope-assisted obliteration of the communication between TC and spinal subarachnoid space (SSS). From 2007 to 2011, six patients - 4 males and 2 females- with an average age of 45 years old were treated. They had lumbar, sciatic and/or perineal pain, and cysts located between S1 and S3. An endoscope-assisted obliteration was conducted, and the outcomes evaluated both clinically and radiologically. After a follow-up of 25.83 months, the results were excellent in 4 patients, good in one and poor in another. The postoperative MRI showed an exclusion of the TCs from the SSS. This confirms that this technique had excellent to good results in 83% of the cases. In general, operative complications are liquor fistula, infections, neurological lesion, and recurrence.

Another surgical technique is from Prof. Warnke. He is a German neurosurgeon working at the neurosurgical department of the Paracelsus-Klinik in Zwickau, Germany. He performs a surgical technique divided into two phases. The first one is the endoscopic phase called techalscopy in the lumbar area, in which the adherences of the nerves and the calcifications are separated through balloon or laser. Afterward, it follows an endoscopic controlled microsurgical resection of the cyst plus a reconstruction of the spinal canal content and of the roof of the canal. Exactly, under endoscopic approach, a subaracno-epidurostomy is performed to improve the CSF flow by reconstruction of the valve function. Then, it is performed a dorsal incision under diaphanoscopy with the dissection of the cyst, which is later closed again through a wrapping with a collagen sponge coated with fibrinogen and thrombin or suturing the fistula. Further, it is used a fat augmentation taking subcutaneous fat tissue from the patient to reimplant and reconstruct the sacral canal and, finally, everything is concluded by a sacral bone reconstruction using bone material or implants (3. Warnke JP, 2021).

CONCLUSION

Tarlov cyst is a rare and underestimated disease, however, a treatable one. Even if it is often responsible for lumbar pain, sacral radiculopathy, and other radiculopathies in the legs, such as sciatica pain, and more symptoms in the genitourinary and perianal region, it is not included in the differential diagnosis of spine diseases and other diseases. Moreover, blurry vision and headache are also described, and this could also lead to wrong diagnoses in other specialties.

The etiopathogenesis is unclear. However, many causes such as degenerative, congenital, inflammatory, and traumatic or iatrogenic (rachicentesis, myelography, peridural anesthesia) are examined. Tarlov cysts are associated to a Leptomeningopathy or an Arachnoiditis and represent a consequence of this inflammation. As it was mentioned above,

this inflammation can bring changes in the flexibility of the nerve roots and reduce the regulatory pressure capacity. This leads to a distortion of rootlets as well as to a chronic elevated CSF pressure with venous congestion, and generally to CSF flow disturbances with formation of cysts at places of low resistance. Moreover, other associations between Tarlov cysts and other diseases were found.

The treatment can be medical and or surgical. The medical therapy is based on pain killers, anti-inflammatory drugs, myorelaxants and physical therapy; on the other hand, the surgical one consists in a sacral laminectomy with a microsurgical fenestration of the cyst. Nowadays, there are also other surgical techniques. Finally, a study about the use of a stem cells therapy for the treatment of the arachnoiditis should be taken under strong consideration.

BIBLIOGRAPHY

- De Sá Márcia Cristina, Carla Tereza D'Angelo, Guilherme Da Ros Malacarne, Pedro Neto, Jorge Pagura. Tarlov cyst: definition, etiopathogenesis, propaedeutic and treatment. *Acta Med Port*, Mar-Apr 2008;21(2):171-8. Epub 2008 Jul 26.
- Prashad Bhagwat, Anil K Jain, Ish K Dhammi. Tarlov cyst: Case report and review of literature, *Indian J Orthop*. 2007 Oct-Dec; 41(4): 401-403.
- Warnke Jan-Peter MD PhD. Online Presentation "Tarlov cyst and Pain". Crowdcast 17th of March 2021, Paracelsus-Klinik Zwickau.
- Vidgis Thompson Foundation, 2022. Beschwerden und Symptomen, Diagnose von Arachnoiditis and Tarlov-Zysten (Diagnosis of Arachnoiditis and Tarlov cysts). www.vidgis-thompson-foundation.org.
- Fernández-Cuadros M E, L M Martín-Martín, M J Albaladejo-Florín, S Álava-Rabasa, O S Pérez-Moro. Tarlov cyst and faecal incontinence, a case report and literature review. Epub 2019 Oct 1/Rehabilitación (Madr) Jul-Sep 2020
- Lim V M, Rohit Khanna, Olga Kalinkin, Mario E Castellanos, Michael Hibner. Evaluating the discordant relationship between Tarlov cysts and symptoms of pudendal neuralgia. Epub 2019 Jul 15/AJOG (American Journal of Obstetrics & Gynecology) January 01, 2020
- Klepinowski Tomasz, Wojciech Orbik, Leszek Sagan. Global incidence of spinal perineural Tarlov's cysts and their morphological characteristics: a meta-analysis of 13,266 subjects. *Surg Radiol Anat* 2021 Jun;43(6):855-863/Epub 2021 Jan 16
- Langdown Andrew John, Julian R B Grundy, Nicholas C Birch. The clinical relevance of Tarlov cysts. *J Spinal Disord Tech* 2005 Feb;18(1):29-33.
- Kuhn Félix P, Sonia Hammoud, Marie-Martine Lefèvre-Colau, Serge Poiraudau, Antoine Feydy. Prevalence of simple and complex sacral perineural Tarlov cysts in a French cohort of adults and children. *J Neuroradiol* 2017 Feb;44(1):38-43/Epub 2016 Nov 9
- Wright Michael H, Leann C Denney. A comprehensive review of spinal arachnoiditis. *Orthop Nurs* May-Jun 2003;22(3):215-9; quiz 220-1.
- Demetriades Andreas K. Arachnoiditis and Chiari I malformation. *Acta Neurochir (Wien)* 2021 Jan;163(1):227-228. Epub 2020 Sep 18.
- Heidary M, Respondek M, Klekamp J. Histological and intraoperative evaluations of the arachnoid in patients with Chiari I malformation. *Acta Neurochir (Wien)* 2021 Jan;163(1):219-225.
- Holly LT, Batzdorf U (2019) Chiari malformation and syringomyelia. *J Neurosurg Spine* 31(5): 619-628.
- Klekamp J, Iaconetta G, Batzdorf U, Samii M. Syringomyelia associated with foramen magnum arachnoiditis 2002. *J Neurosurg* 97(3 Suppl): 317-322.
- Radek Fric, Per Kristian Eide. Chiari type 1-a malformation or a syndrome? A critical review. *Acta Neurochir (Wien)* 2020 Jul;162(7):1513-1525; Epub 2019 Oct 28.
- Zatorska Barbara, Ewa Herba, Dorota Pojda-Wilczek, Wojciech Jedrzejewski, Stefan M Pojda. The intracranial hypertension in the course of Arnold-Chiari malformation. *Klin Oczna* 2004; 106(4-5): 657-60.
- Demols P, C Van Nechel. Association of idiopathic intracranial hypertension-Arnold-Chiari deformity: danger! *Bull Soc Belge Ophtalmol* 1998; 268: 153-8.
- Gaurav Vishwasrao Watane, Bhumi Patel, Derek Brown, M Reza Taheri. The Significance of Arachnoid Granulation in Patients with Idiopathic Intracranial Hypertension. *J Comput Assist Tomogr* Mar/Apr 2018; 42(2): 282-285.
- Galiano Rafael, Arantxa Navarré-Gimeno, Vicente Miranda-Gonzalbo, Miguel García-Escrig, Iratxe Jiménez, Luis Aznar. Adhesive arachnoiditis and dorsal syringomyelia secondary to subarachnoid hemorrhage. *Rev Neurol* 2013 Jun 16;56(12):639-40.
- Ishizaka Shunsuke, Kentaro Hayashi, Munehiro Otsuka, Shuji Fukuda, Keishi Tsunoda, Ryujiro Ushijima, Naoki Kitagawa, Kazuhiko Suyama, Izumi Nagata. Syringomyelia and arachnoid cysts associated with spinal arachnoiditis following subarachnoid hemorrhage. *Neurol Med Chir (Tokyo)* 2012; 52(9):686-90.
- Vandertop W. Peter, Syringomyelia, *Neuropediatrics* 2014 Feb; 45(1): 3-9. Epub 2013 Nov 22.
- Milhorat TH. Classification of syringomyelia. *Neurosurg Focus* 2000; 8 (3) E
- Ikenouchi J, Uwabe C, Nakatsu T, Hirose M, Shioita K. Embryogenic hydromyelia: cystic dilatation of the lumbosacral neural tube in human embryos. *Acta Neuropathol* 2002; 103 (3) 248-254.
- Ravaglia S, Bogdanov EI, Pichiecchio A, Bergamaschi R, Moglia A, Mikhaylov IM. Pathogenetic role of myelitis for syringomyelia. *Clin Neurol Neurosurg* 2007; 109 (6) 541-546.
- Charles JA, Berger M, Cook SD. Thoracic syringomyelia and suspected multiple sclerosis; cause and effect or coincidence? *Neurology* 2004; 63 (1) 185-186.
- Marangoni S, Argentiero V, Tavolato B. Neurosarcoidosis. Clinical description of 7 cases with a proposal for a new diagnostic strategy. *J Neurol* 2006; 253 (4) 488-495.
- Iskandar BJ, Oakes WJ, McLaughlin C, Osumi AK, Tien RD. Terminal syringohydromyelia and occult spi-

- nal dysraphism. *J Neurosurg* 1994; 81 (4) 513-519.
28. Chavhan GB, Babyn PS, Jankharia BG, Cheng HL, Shroff MM. Steady-state MR imaging sequences: physics, classification, and clinical applications. *Radiographics* 2008; 28 (4) 1147-1160.
 29. Roser F, Ebner FH, Danz S, et al. Three-dimensional constructive interference in steady-state magnetic resonance imaging in syringomyelia: advantages over conventional imaging. *J Neurosurg Spine* 2008; 8 (5) 429-435.
 30. Bunck AC, Kröger JR, Jüttner A, et al. Magnetic resonance 4D flow characteristics of cerebrospinal fluid at the craniocervical junction and the cervical spinal canal. *Eur Radiol* 2011; 21 (8) 1788-1796.
 31. Vandertop WP. Progression of terminal syrinx in occult spina bifida. *Childs Nerv Syst* 2003; 19 (5-6) 267, author reply 268.
 32. Del Castillo-Calcaño Juan D, Rodrigo Navarro-Ramírez, Jonathan Nakhla, Eliana Kim, Roger Härtl. Minimally Invasive Treatment for a Sacral Tarlov Cyst Through Tubular Retractors. *World Neurosurg* 2017 Dec; 108:993. e9-993.e11. Epub 2017 Sep 7.
 33. Mezzadri Juan, Santiago Gonzalez Abbati, Pablo Jalon. Tarlov cysts: endoscope-assisted obliteration of the communication with the spinal subarachnoid space. *J Neurol Surg A Cent Eur Neurosurg* 2014 Nov;75(6):462-6. Epub 2014 Mar 28.
 34. Dehaine V, B Wechsler, J M Ziza, C de Gennes, G Robain, D Fohanno, J Metzger, P Godeau. Coccygodynia disclosing Tarlov's cysts. *Rev Med Interne* Jul-Aug 1990;11(4):280-4.
 35. Ahn So Yoon, Yun Sil Chang, Won Soon Park. Mesenchymal stem cells transplantation for neuroprotection in preterm infants with severe intraventricular hemorrhage. *Korean J Pediatr* 2014 Jun; Epub 2014 Jun 30.
 36. Villines Z, Morrison W. Arachnoiditis: symptoms, diagnosis, and outlook. *MedicalNewsToday*, 2018 February 2.
 37. Fraser C. Henderson Sr., Claudiu Austin, Edward Benzel, Paolo Bolognese, Richard Ellenbogen, Clair A Franco-mano, et al. Neurological and spinal manifestations of the Ehlers-Danlos syndromes. *American Journal of Medical Genetics Part C: Seminars in Medical Genetics*, Volume 175, Issue 1/p. 195-211, Epub 2017 February 21.